

HIP FOLLOW-UP

It is important to review the status of your hip implant(s) during an office visit at six weeks, one year, two years, and every other year postoperatively thereafter for your safety even though you are feeling great. Long distance follow-up evaluations for out-of- state patients are fine. We would like to ask you to complete the following evaluation protocol.

- 1) *Hip questionnaire:* We keep track of each joint separately in our database. Therefore, I would like to request that you fill out a self rating form for **EACH** hip, even if both are identical. Please send to us.
- 2) *Hip X-Ray :*
 - Add your name to the x-ray request
 - Have the x-ray of your hip(s) done at your local hospital or radiologist and request a CD copy of this x-ray be sent to us

As soon as we receive all of the above, I will review them and send you a written response. If you prefer to travel here for an office visit for evaluation, please call our appointment line to arrange this (803) 256-4107 (routine office charges will apply). If you are having significant problems with your hip, I will need to see you in the office for complete examination to best diagnose it.

Thank you for your attention to this matter. If you have any questions, please contact us for assistance.

Thomas P. Gross MD

Lee Webb, DNP, APRN, FNP-C

Attached Forms:

1. *Follow up hip questionnaire* (page 3-8)
2. *Hip XR request and radiologist's instructions* (page 9-11)

E-mail: grosspatientfollowup@midlandsortho.com

Call: (803) 933-6127

FAX: (803) 933-6339

If you don't have any questions, please follow the protocol and fill out each form below, then FEDEX the packet to:

Dr. Thomas P. Gross
Attn: Hip follow-up
Midlands Orthopaedics & Neurosurgery
1910 Blanding St.
Columbia, SC 29201

Hip Follow-Up Form

Name: _____ Date _____

Follow-up Information

1. Where was this form completed?

- Office
- Phone
- Mail-In
- Internet

2. This questionnaire is for the evaluation of my (side) hip.

- Left
- Right

3. I have had problems with my (side) hip(s).

- Left
- Right
- Both

4. Dr. Gross has operated on my (side) hip(s).

- Left
- Right
- Both

5. Another surgeon has operated on my (side) hip(s).

- Left
- Right
- Both

6. Dr. Gross performed the followed operation(s) on me:

- Total hip replacement
- Hip resurfacing
- Revision hip surgery
- Other: _____

Complications

1. List any complications you had post-surgery:

- None
- Wound Infection
- Deep Venous Thrombosis
- Pulmonary Embolus (Blood clot travelling to lungs)
- Partial Sciatic Palsy (Nerve injury)
- Dislocation
- Fracture
- Loosened implant
- Other: _____

2. Did you have any complications that required further surgery?

- Yes; Please explain: _____
- No

Clinical Function Score

1. What category most closely represents your pain level?

- None, or so insignificant that I ignore it
- Regularly slight
- Mild
- Moderate
- Severe
- Disabled


2. My hip pain is located in my (check all that apply):

- No pain
- Groin
- Front of thigh
- Buttock
- Side of thigh
- Side of hip, near scar
- Other pain: _____

3. Please circle your regular pain level on the following scale.



4. Please circle your highest hip pain level on the following scale.



5. Please indicate the severity of your limp, if any.

- None
- Slight
- Mild
- Moderate
- Severe
- Disabled

6. Please indicate your use of support, if any.

- None required
- Use of a cane or a stick for long walks or high activity only
- Use of a cane or a stick almost always
- Use of one crutch almost always
- Use of two crutches or a walker
- Unable to move across the room

7. I am able to walk _____ without a break:

- Over one mile/Unlimited
- 6 blocks or roughly 30 minutes
- 2-3 blocks or roughly 10-15 minutes
- Indoor walking only
- Bed and chair only

8. Which of the following describes how you take stairs?

- Normally foot-over-foot without NEEDING the railing
- Normally using the railing
- Leading with non-painful hip one step at a time
- Cannot take the stairs

9. I am able to put socks/shoes on....

- With ease
- With difficulty
- Unable to put socks or shoes on without help

10. Under what circumstances can you sit comfortably?

- Any chair/1+ hour
- High chair/30 minutes
- Unable to sit comfortably

11. Are you able to get in and out of a vehicle without help?

- Yes
- No

12. Please list any unrelated orthopaedic issues that you believe might effect your hip function score (i.e. bad back, arthritis in other hip, non-hip pain, etc.)

- Yes; please list: _____
- No

13. How is your hip joint now compared to before surgery?

- Better than my normal, healthy, pre-arthritis/damaged hip
- Feels just like my normal, healthy, pre-arthritis/damaged hip
- Much better than before surgery, with minor aches and pains
- Somewhat better than before surgery
- About the same
- Worse than before surgery

Activity Score

1. Which best describes your current level of activity? (Please circle one.)

Class	Description
1	Wholly inactive, dependent on others, and can not leave residence
2	Mostly inactive or restricted to minimum activities of daily living
3	Sometimes participates in mild activities, such as walking, limited housework, and limited shopping
4	Regularly participates in mild activities
5	Sometimes participates in moderate activities, such as swimming, or could do unlimited housework or shopping
6	Regularly participates in moderate activities
7	Regularly participates in active events, such as bicycling
8	Regularly participates in active events, such as bowling or golf
9	Sometimes participates in impact sports, such as jogging, tennis, skiing, acrobatics, ballet, heavy labor, or backpacking
10	Regularly participates in impact sports

2. Please list any activities that you participate in regularly.

3. Please list any vigorous activities that you occasionally participate in.

4. My activity is now _____ compared to before surgery.

- Higher
- Similar
- Lower

Conclusions

5. Overall, are you happy with your decision to have this surgery?

- Yes
- No

6. Do you have any comments?

MIDLANDS
orthopaedics
& NEUROSURGERY

(803) 256-4107
1910 Blanding St.
Columbia, SC 29201
1013 Lake Murray Blvd.
Irmo, SC 29063

R_x FOR _____
ADDRESS _____ DATE _____

Please select/circle ONE section (either 1, 2, or 3) to ensure the appropriate xrays are obtained from the patient's radiology facility.

1. LEFT
 - a. Diagnoses:
 - i. Osteoarthritis (OA) of the hip – **M16.12**
 - ii. Hip pain – **M25.552**
2. RIGHT
 - a. Diagnoses:
 - i. Osteoarthritis (OA) of the hip – **M16.11**
 - ii. Hip pain – **M25.551**
3. BILATERAL
 - a. Diagnoses:
 - i. Osteoarthritis (OA) of the hip – **M16.10**
 - ii. Hip pain – **M25.559**

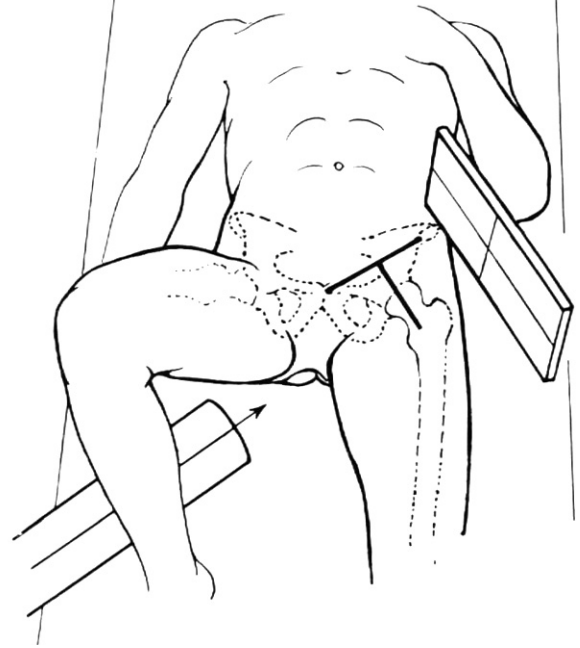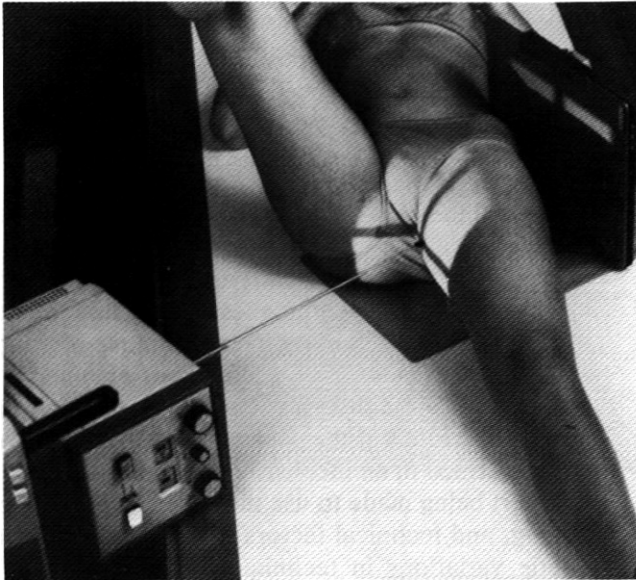
Views (please include all of the following):

1. AP Pelvis Standing (Please label as "STANDING")
2. AP Pelvis Supine (Please label as "SUPINE")
3. Johnson Lateral/Cross-table Lateral

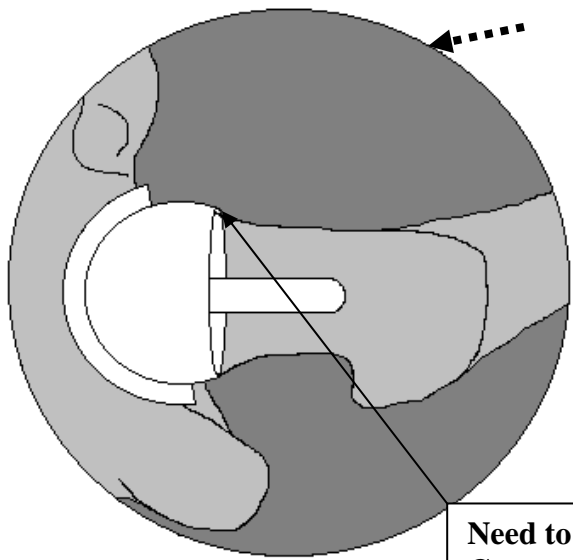
Please provide the patient with a CD digital copy of these x-rays for my review, and mail to:

Midlands Orthopaedics & Neurosurgery

ATTN: Gross follow-up
1910 Blanding Street
Columbia, SC 29201



Instructions for Johnson Lateral for patients post hip resurfacing



The perfect true lateral:

- Visualize the anterior and posterior neck, just inferior to the femoral component.
- **The more neck Anteversion, the more the hip needs to be flexed...**

Need to see cortex at Component-Neck junction

C

Fig. 10-2. True-lateral (Johnson or cross-table) lateral view. (A) Position of patient. The long axis of the left femoral neck is localized by imaging a line drawn between the anterosuperior iliac spine and the superior border of the symphysis pubis, determining the midpoint of the line, and then palpating the greater trochanter and imaging a point 1 inch

distal to it. A line drawn between these two points parallels the long axis of the femoral neck. **(B)** The cassette is placed in the vertical position with its cephalad border in contact with the body at the level of the iliac crest; it is parallel with the long axis of the femoral neck. The central ray is perpendicular to the long axis of the femoral neck and cassette and is centered 2.5 inches below the point of intersection of the localization lines. **(C)** Roentgenogram of hybrid surface arthroplasty. The ischium is toward the bottom of the image. (Fig. B, from Ballinger PW: Merrill's Atlas of Radiographic Positions and Radiologic Procedures, 6th Ed., Vol. 1. CV Mosby, St. Louis, 1986, with permission.)