

Intraoperative Radiographs for Placing Acetabular Components in Hip Resurfacing Arthroplasty

Thomas P. Gross MD, Fei Liu PhD, Lee Webb NP

© The Association of Bone and Joint Surgeons® 2010

Abstract

Background Various clinical and biomechanical studies suggest certain acetabular positions may be associated with higher wear and failure rates in modern metal-on-metal hip resurfacing arthroplasties. However, there are no widely available, reliable, and cost-effective surgical techniques that ensure surgeons are able to place an acetabular component within the safe range of inclination angles after hip resurfacing surgeries.

Questions/purposes We investigated the accuracy of intraoperative radiographs to determine the acetabular inclination angle in resurfacing arthroplasty procedures.

Patients and Methods The study group included the first 100 resurfacing arthroplasties performed after we started routinely checking the intraoperative acetabular inclination angles. The acetabular component was repositioned if the intraoperative acetabular inclination angle was out of the target range of 30° to 50°. The control group included the previous 100 resurfacing arthroplasties performed without the benefit of intraoperative radiographs. A posterior minimally invasive surgical approach was used in both groups. Demographics and diagnoses were similar in both groups.

One of the authors (TPG) has received royalties from Biomet Inc (Warsaw, IN). The remaining authors certify that they have no commercial associations (eg, consultancies, stock ownership, equity interest, patent/licensing arrangements, etc) that might pose a conflict of interest in connection with the submitted article.

Each author certifies that his or her institution approved the human protocol for this investigation and that all investigations were conducted in conformity with ethical principles of research.

T. P. Gross, F. Liu (✉), L. Webb
Midlands Orthopaedics, p. a., 1910 Blanding Street,
Columbia, SC 29201-3520, USA
e-mail: grossortho@yahoo.com; feilresearch@gmail.com

Results The average (\pm SD) difference between the intraoperative and 6-week radiographs was $2.7^\circ \pm 2.5^\circ$. The acetabular inclination angles at 6-week followup were within the targeted range more frequently in the study group than in the control group (outliers: 4% versus 29%).

Conclusions These data suggest a single intraoperative radiograph is a quick, reliable, and cost-effective method for ensuring the acetabular inclination angle is within the targeted range.

Level of Evidence Level III, therapeutic study. See Guidelines for Authors for a complete description of levels of evidence.

Introduction

The use of hip resurfacing arthroplasty (HRA) has been resurgent with the development of modern designs of metal-on-metal bearings since the late 1990s [2, 4, 7, 8, 11, 15, 21, 28]. Recent studies reported revision rates of 1% to 5% at an average of 5 to 7 years in young and active patients after HRA [2, 15, 21, 28]. Even though femoral neck fracture and femoral loosening were formerly reported as the most common failure modes in these studies [2, 4, 21], revision related to the acetabular component is being recognized more frequently in recent reports [8, 11]. Previously, higher dislocation rates and increased wear rates were well-documented in standard THA with improper acetabular inclination angles [12, 20, 22, 31]. Although large metal bearings are resistant to dislocation even with relatively high angles of inclination, several clinical studies have implicated high cup inclination angles in wear-related failures after HRA [4, 13, 33]. One biomechanical analysis suggested higher wear rates after two million cycles when acetabular component inclination

angles were greater than 55° in 39-mm metal-on-metal bearing hip implants [31]. Also, while several studies [3, 8] suggest the upper limit for ideal inclination angle for large metal bearings is approximately 55°, we found no data suggesting a lower limit.

Many methods, including visual inspection [32], use of specialized jigs [23], intraoperative fluoroscopic guidance [21], image-free navigation [16, 24], and CT-based computer navigation [10, 17, 27], reportedly assist surgeons in achieving the safe target during the placement of acetabular components. However, all of these techniques have disadvantages, such as a lack of accuracy, high cost, a requirement for special training, and extra preparation and operating room (OR) time. There are no widely available, reliable, and cost-effective surgical techniques that ensure surgeons are able to place an acetabular component within the safe range of inclination angles after HRAs.

We therefore (1) asked whether a single intraoperative AP pelvis radiograph would ensure the inclination angle of an acetabular component was in a target range of 30° to 50° during a metal-on-metal HRA; (2) if so, asked whether the intraoperative assessment of inclination was accurate when compared to the standard postoperative supine AP pelvis radiographs and whether this method was time-consuming compared to our routine surgical protocol; and (3) developed guidelines to prevent outliers with acetabular inclination angles out of the target range of 30° to 50° after HRA.

Patients and Methods

The senior author (TPG) had performed more than 1100 metal-on-metal HRAs and had already focused on placing acetabular components with acetabular inclination angles within the range of 30° to 50° before this study. He began routinely using plane radiographs to check the inclination angles of the acetabular components during HRA procedures in November 2007. The study group included the first 100 HRAs performed with the aid of an intraoperative radiograph between November 2007 and March 2008. To determine whether this technique led to an improvement in component positions, the study group was compared to a control group consisting of the last 100 HRAs performed between July 2007 and November 2007, just before the protocol of an intraoperative radiographic check was started. No patients were excluded from this study for any reason. For the study group, all inclination angles of acetabular components on the intraoperative (intraoperative acetabular inclination angle [IOIA]), immediate recovery room (recovery room acetabular inclination angle [RRIA]), and 6-week followup (6-week followup acetabular inclination angle [SFIA]) radiographs were prospectively

measured by the same author (LW). The radiographic records (RRIA and SFIA) of the control group were retrospectively reviewed. All of the selected cases had good-quality AP pelvis radiographs in the recovery room and at their 6-week followup for analysis of the acetabular inclination angle. We defined a possible cup shift when a measured change in component position between SFIA and RRIA was greater than the average difference plus three SDs of variability. There were no differences between the two groups with respect to demographic and clinical parameters (Table 1).

All HRA procedures were performed (not supervised) by the senior author (TPG) with the same first assistant (LW) through a posterior minimally invasive approach. The Recap® femoral resurfacing component (Biomet, Inc, Warsaw, IN) was combined with the Magnum™ acetabular component (Biomet, Inc) in all cases. Patients were placed in the lateral decubitus position using a standard OSI positioning system (OSI-Orthopaedic Systems Inc, Union City, CA) consisting of a set of four pads clamped to the OR table to hold the patient firmly in position. The radiology staff was called when acetabular reaming had begun. In both groups, the acetabular bone was underreamed by 1 mm. A 1 mm smaller smooth trial component was placed to assess the appropriateness of reaming. Then the component was impacted. No alignment guides were used. If the component position was not perfect by visual criteria, an edge tamp was used and the cup was impacted again with a secondary impactor. If this method was unsuccessful, the cup was removed and

Table 1. Demographic and intraoperative data for both groups

Variable	Study group	Control group	p Value
Number of hips	100	100	
Age (years)*	51 ± 7	52 ± 9	0.70 [†]
Gender			0.44 [‡]
Women	29	32	
Men	71	68	
Diagnosis			0.20 [‡]
Osteoarthritis	73	69	
Dysplasia	18	13	
Posttrauma	4	5	
Avascular necrosis	3	9	
Other	2	4	
Component size (mm)*			
Acetabular	56 ± 4	56 ± 4	0.81 [§]
Femoral	49 ± 6	50 ± 4	0.72 [§]

* Values are expressed as mean ± SD; all other values are expressed as number of hips; [†]the data are normally distributed; the standard t test was used here; [‡]the chi square test was used here; [§]the data are not normally distributed; a Wilcoxon-Mann-Whitney test was used here.

reimpacted with the primary impactor. In no cases did we change to another component or use supplementary fixation. In the study group, as soon as the acetabular component was impacted, a portable crosstable AP pelvis radiograph was obtained. A sterile drape was clamped to the front of the patient, and the portable radiograph unit was moved into place. The anesthetist tilted the OR table to align the anterior plane of the pelvis visually perpendicular to the floor according to the surgeon's best estimate. The xray beam was angled approximately 10° caudal. The xray plate was placed on a stand posterior to the patient, oriented perpendicular to the xray beam, and covered with a sterile sheet. While the radiograph was being developed, the supplemental sterile drape was removed, the femoral component was implanted, and closure was started to avoid unnecessary delay. The film was immediately developed and hung on the OR view box. The inclination angle of the acetabular component was measured by drawing a line across the inferior pubic rami and another line across the opening face of the acetabular component [6] (Fig. 1). The acetabular inclination angles were measured on the intraoperative radiograph by an assistant (LW) and immediately reviewed by the senior author (TPG). The component position was not changed if the inclination angle was in the target range of 30° to 50°. If the component required adjustment, the process of repositioning occurred again. A new radiograph was then ordered in the recovery room. The extra OR time required to obtain this intraoperative radiograph was measured in 20 consecutive cases.

Twenty HRAs were randomly selected and their 6-week followup radiographs were measured three times each by two observers (FL, LW) to evaluate the intraobserver and interobserver variability of this technique. One author (FL) did not have any experience measuring acetabular component positions on radiographs before this study. The average absolute interobserver variability (\pm SD) was $2.4^\circ \pm 3.0^\circ$ (range, 0.4°–5.5°), and the average absolute

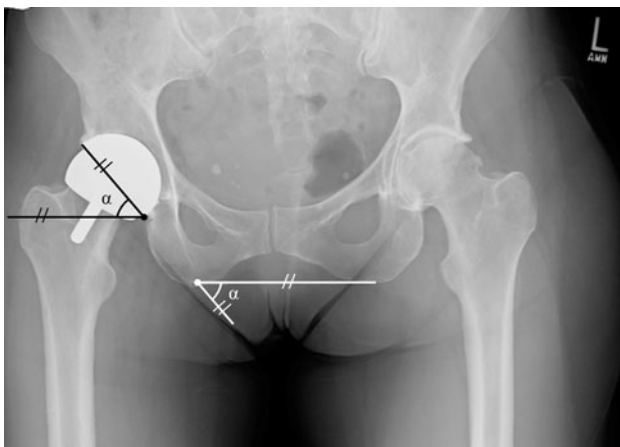


Fig. 1 Measurement of the acetabular inclination angle (α) is shown.

intraobserver variability (\pm SD) was $0.9^\circ \pm 0.3^\circ$ (range, 0.4°–1.6°). The average correlation coefficient value was 0.89 (95% confidence interval, 0.74–0.95) for intraobserver variability and 0.99 (95% confidence interval, 0.98–0.99) for interobserver variability (correlation coefficients range from 0 to 1, with 0 representing no agreement and 1 representing perfect agreement [1]).

We evaluated the normal distribution of numeric parameters with the use of Shapiro-Wilk W tests. If the tested parameters were normally distributed, we determined the differences between the study and control groups with the use of standard t tests; otherwise, we evaluated the differences with the use of nonparametric Wilcoxon-Mann-Whitney tests. We evaluated the differences of categorical parameters between the two groups with the use of chi square tests. To assess the differences among IOIA, RRIA, and SFIA in each group, we calculated the mean and SD for each of them. A univariable linear regression was performed based on a standard least-squares technique with a 95% confidence interval to determine the target range of IOIA, which ensures SFIA falls into the safe range of 30° to 50°. Cases where the acetabular component was determined to be possibly shifted were excluded from the data used to build the model. All statistical analyses were performed with the use of OrthoTrack (Midlands Orthopaedics, PA, Columbia, SC), except the regression analysis, which was generated with the use of JMP (SAS Institute, Inc, Cary, NC). Institutional Review Board approval was obtained for this study.

Results

There were more cases ($p < 0.001$) with an acetabular inclination angle within the target range in the study group than in the control group, both on the immediate recovery room and on the postoperative 6-week followup radiographs (Table 2). In the study group, there was one case with a RRIA of more than 50° (51°) and four cases with a SFIA of less than 30° (range, 20°–26°). In the control group, there were 16 cases with a RRIA of more than 50° (range, 51°–57°) and one case with a RRIA of less than 30° (29°); at the 6-week followup, there were 29 outliers with a SFIA of more than 50° (range, 51°–59°).

For the study group, the average absolute difference (\pm SD) was $2.5^\circ \pm 2.0^\circ$ (range, 0°–10°) between IOIA and RRIA, $2.7^\circ \pm 2.5^\circ$ (range, 0°–14°) between IOIA and SFIA, and $2.1^\circ \pm 1.8^\circ$ (range, 0°–10°) between RRIA and SFIA. For the control group, the average absolute difference (\pm SD) between RRIA and SFIA was $2.1^\circ \pm 1.7^\circ$ (range, 0°–13°). The average additional intraoperative radiograph time (\pm SD) during which the operation was delayed was 116 ± 28 seconds per case.

Table 2. Intraoperative, recovery room, and 6-week followup acetabular inclination angles between the study and control groups

Variable	Study group			Control group		
	Average \pm SD	Range	Missing rate	Average \pm SD	Range	Missing rate
IOIA	39° \pm 5°	30°–50°	0%	NA	NA	NA
RRIA	39° \pm 4°	30°–51°	1%	46° \pm 5°	29°–56°	17%
SFIA	39° \pm 5°	20°–50°	4%	47° \pm 5°	51°–59°	29%

IOIA = intraoperative acetabular inclination angle; RRIA = recovery room acetabular inclination angle; SFIA = 6-week followup acetabular inclination angle; NA = not applicable.

Table 3. Possible asymptomatic acetabular component shifts

Case	IOIA	RRIA	SFIA	Latest Harris hip score*
Study group				
1	38°	33°	24°	100
2	45°	36°	20°	82
Control group				
1	NA	51°	59°	100

* Minimal 2-year followup; IOIA = intraoperative acetabular inclination angle; RRIA = recovery room acetabular inclination angle; SFIA = 6-week followup acetabular inclination angle; NA = not applicable.

In the study group, the acetabular component appeared shifted between the immediate recovery room and the 6-week radiographs in two cases (Table 3). Both of these acetabular components were now out of the target range, with SFIA of less than 30°. These two cases were excluded from the data to generate the regression model. To achieve a SFIA in the target range of 30° to 50° with a 95% confidence interval, the surgeon had to keep the IOIA in the range of 32° to 46° according to the regression model ($R^2 = 0.52$) (Fig. 2). In the control group, the acetabular component was suspected of having shifted in one case. It shifted to a more inclined position outside of the target range (Table 3). There was no difference ($p = 0.56$) in the incidence of acetabular component shifting between the two groups. All three patients with shifted acetabular components were doing well with a stable component at their minimal 2-year followup visit. There were no acetabular revisions or dislocations in either group. One femoral component was revised in each group due to femoral neck fracture. The acetabular component was left in place in both cases. The patients were doing well at the latest followup. Because the acetabular components were not revised, they were not excluded from this study.

Discussion

It appears likely hip arthroplasty based on large metal-on-metal bearings will have increased metal ion levels and

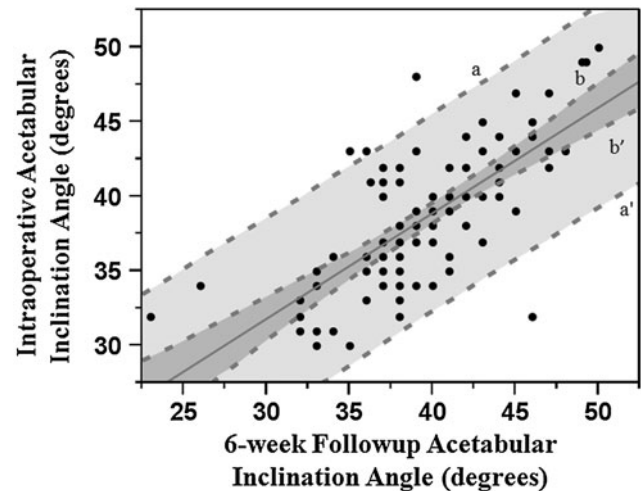


Fig. 2 A graph shows the regression model fitting of the acetabular inclination angles intraoperatively versus at 6-week followup ($R^2 = 0.52$). Black dots = original data points; Lines a and a' = 95% confidence limits of an individual predicted value; Lines b and b' = 95% confidence curves of predicted values.

higher rates of wear-related failure with higher acetabular inclination angles [20, 21, 31]. Previously, a few studies were directed at proper femoral component stem orientation in HRA [19, 26, 27]. However, it now appears proper placement of the acetabular component may be even more critical to the success of this procedure [8, 9, 11, 21, 30]. We investigated the value of using a single intraoperative portable crosstable AP radiograph to improve the accuracy of placing the acetabular component within a target range of inclination.

Our study is associated with some limitations. First, the data analysis and the regression model in this study were based on cases from only one surgeon who had performed a large number of HRAs; more variability would likely occur when this technique is used by less experienced surgeons. Second, we could not determine whether cup repositioning led to asymptomatic cup shifts because we were not aware of the problem of possible cup shifts during this study and we did not record when and how often cups were repositioned in both groups. It is possible there were more cups repositioned based on unacceptable

radiographic criteria in the study group. Uncertainty of cup position without a radiograph could have led to more cup changes in the control group as well. We found no difference in the incidence of possible cup shifts between the two groups. More accurate standardized radiographic and accurate intraoperative logs of details of cup insertion and repositioning should be required in the future studies to answer these questions. Third, we could not determine an acetabular anteversion angle. We are unaware of any rigorously established ideal target criteria for acetabular anteversion position in HRA. Until further data become available, we believe it is reasonable to keep the acetabular inclination angle of 30° to 50°, with the anteversion determined intraoperatively by surgeons to maximize the ROM and to avoid impingement in both flexion and extension.

A “safe” zone of acetabular component position was suggested for small-bearing metal-on-polyethylene THA in a retrospective study [20]. Although this study had some weaknesses, the safe range of 30° to 50° suggested in that study has been generally accepted as a gold standard by surgeons [14, 16, 25], which was also targeted in our study. An AP pelvis radiograph remains a universal tool for assessing acetabular inclination angles after hip arthroplasties in the United States. Generally, the inaccuracy in radiographic measurements of inclination angles is introduced when patients are lying on their side on an OR table. In this study, we found our overall frequency of ending up in this desired range at 6-week followup was improved after we began checking the intraoperative radiograph (4% versus 29%). Thus, our data suggest, despite the disadvantages of using plane radiographs, the intraoperative radiograph can still provide enough information to ensure the inclination angle of an acetabular component was in a target range of 30° to 50° during a metal-on-metal HRA.

Normally, it is difficult to place an acetabular component within the target range in one attempt for every case without any assistance. Numerous studies have documented surgical navigation holds the promise for providing most accurate intraoperative guidance for acetabular component position [10, 16, 29, 34]. However, the equipment is not available to most surgeons. Two German studies performed cost-saving analyses and reported the incremental cost of using a navigation system in joint arthroplasties ranged from 300 Euro to 442 Euro per case [5, 18]. Also, surgical navigation is usually more time-consuming. A study reported an additional 10 to 15 minutes of OR time was needed to install the image-guided navigation system [10]. Comparatively, our technique required less than 2 minutes of additional OR time in our study. On the other hand, when acetabular inclination is evaluated, errors may be added up due to data calibration and data acquisition by introducing navigation system

Table 4. Comparison of accuracy among different studies

Study	Method	Absolute deviation
Kalteis et al. [16] (2005)	Image-free navigation system	2.3° ± 2.8°
Kalteis et al. [16] (2005)	Free hand	6.2° ± 7.0°
DiGioia et al. [10] (1998)	Image-guided navigation system	3.7° ± 2.6°
Ybinger et al. [34] (2007)	Imageless navigation system	3.5° ± 4.4°
Gross et al.	Intraoperative radiograph	2.7° ± 2.5°

Values are expressed as mean ± SD.

(Table 4). Furthermore, measurements using current navigation systems are based on the anterior pelvic plane and cannot be directly compared with measurements made on conventional supine or standing radiographs. These differences require further complicated translations that may result in additional possible errors [22]. Fluoroscopy has also been suggested in metal-on-metal HRA [21]. The major disadvantage is the inability to actually perform a measurement of an inclination angle and a surgeon has to make a visual estimate of the angle because the whole pelvis cannot be captured on one film. Intraoperative radiographic evaluation does not allow guided placement; it only allows checking a final position. To avoid repositioning an acetabular component, another option would be to implant a trial component, obtain a radiograph, and then implant an actual component. This might avoid changing the actual cup position. It is unknown whether reorienting an acetabular component influences the durability of the implant. There may be a trade-off between accepting a suboptimal position and accepting some risk of cup shift or failure of ingrowth due to the process of repositioning the component. Further studies will be required to answer these questions.

We suspect surgical navigation technology will eventually emerge as the most accurate and reproducible method of placing acetabular components with three-dimensional accuracy. However, several obstacles remain. First, it is not clear they are currently more accurate than cheaper and quicker methods. Second, substantial additional costs for these advanced technologies may not be supported in the current climate of cost containment. Therefore, we currently suggest the use of a single portable intraoperative radiograph as an inexpensive, quick, and widely available method to improve the frequency of placing the acetabular component within the desired range of inclination angles in metal-on-metal HRA. Also, we believe this technique could be applicable to any other metal-on-metal hip arthroplasty.

References

- Tamhane AC, Dunlop DD. *Statistics and Data Analysis: From Elementary to Intermediate*. Upper Saddle River, NJ: Prentice Hall; 2000.
- Amstutz HC, Le Duff MJ. Eleven years of experience with metal-on-metal hybrid hip resurfacing: a review of 1000 Conserve Plus. *J Arthroplasty*. 2008;23:36–43.
- Brodner W, Grubl A, Jankovsky R, Meisinger V, Lehr S, Gottsauner-Wolf F. Cup inclination and serum concentration of cobalt and chromium after metal-on-metal total hip arthroplasty. *J Arthroplasty*. 2004;19:66–70.
- Campbell P, Beaulé PE, Ebraamzadeh E, LeDuff M, De Smet K, Lu Z, Amstutz HC. The John Charnley Award. A study of implant failure in metal-on-metal surface arthroplasties. *Clin Orthop Relat Res*. 2006;453:35–46.
- Cerha O, Kirschner S, Gunther KP, Lutzner J. Cost analysis for navigation in knee endoprosthetics. *Orthopade*. 2009;38:1235–1240.
- Crowninshield RD, Maloney WJ, Wentz DH, Humphrey SM, Blanchard CR. Biomechanics of large femoral heads: what they do and don't do. *Clin Orthop Relat Res*. 2004;429:102–107.
- Daniel J, Pynsent PB, McMinn DJ. Metal-on-metal resurfacing of the hip in patients under the age of 55 years with osteoarthritis. *J Bone Joint Surg Br*. 2004;86:177–184.
- De Haan R, Campbell PA, Su EP, De Smet KA. Revision of metal-on-metal resurfacing arthroplasty of the hip: the influence of malpositioning of the components. *J Bone Joint Surg Br*. 2008;90:1158–1163.
- De Haan R, Pattyn C, Gill HS, Murray DW, Campbell PA, De Smet K. Correlation between inclination of the acetabular component and metal ion levels in metal-on-metal hip resurfacing replacement. *J Bone Joint Surg Br*. 2008;90:1291–1297.
- DiGioia AM, Jaramaz B, Blackwell M, Simon DA, Morgan F, Moody JE, Nikou C, Colgan BD, Aston CA, Labarca RS, Kischell E, Kanade T. The Otto Aufranc Award. Image guided navigation system to measure intraoperatively acetabular implant alignment. *Clin Orthop Relat Res*. 1998;355:8–22.
- Gross TP, Liu F. Metal-on-metal hip resurfacing with an uncemented femoral component: a seven-year follow-up study. *J Bone Joint Surg Am*. 2008;90(Suppl 3):32–37.
- Haaker RG, Tiedjen K, Ottersbach A, Rubenthaler F, Stockheim M, Stiehl JB. Comparison of conventional versus computer-navigated acetabular component insertion. *J Arthroplasty*. 2007;22:151–159.
- Hart AJ, Buddhdev P, Winship P, Faria N, Powell JJ, Skinner JA. Cup inclination angle of greater than 50 degrees increases whole blood concentrations of cobalt and chromium ions after metal-on-metal hip resurfacing. *Hip Int*. 2008;18:212–219.
- Hassan DM, Johnston GH, Dust WN, Watson G, Dolovich AT. Accuracy of intraoperative assessment of acetabular prosthesis placement. *J Arthroplasty*. 1998;13:80–84.
- Hing CB, Back DL, Bailey M, Young DA, Dalziel RE, Shimmin AJ. The results of primary Birmingham hip resurfacings at a mean of five years: an independent prospective review of the first 230 hips. *J Bone Joint Surg Br*. 2007;89:1431–1438.
- Kalteis T, Handel M, Herold T, Perlick L, Baethis H, Grifka J. Greater accuracy in positioning of the acetabular cup by using an image-free navigation system. *Int Orthop*. 2005;29:272–276.
- Kalteis T, Handel M, Herold T, Perlick L, Paetzl C, Grifka J. Position of the acetabular cup—accuracy of radiographic calculation compared to CT-based measurement. *Eur J Radiol*. 2006;58:294–300.
- König DP, Michael JW, Eysel P, Munnich U, Lichtenstein T, Schnurr C. Computer-assisted joint replacement surgery: financial and clinical impact for a specialised orthopaedic hospital. *Z Orthop Unfall*. 2009;147:669–674.
- Kruger S, Zambelli PY, Leyvraz PF, Jolles BM. Computer-assisted placement technique in hip resurfacing arthroplasty: improvement in accuracy? *Int Orthop*. 2009;33:27–33.
- Lewinnek GE, Lewis JL, Tarr R, Compere CL, Zimmerman JR. Dislocations after total hip-replacement arthroplasties. *J Bone Joint Surg Am*. 1978;60:217–220.
- Mont MA, Schmalzried TP. Modern metal-on-metal hip resurfacing: important observations from the first ten years. *J Bone Joint Surg Am*. 2008;90(Suppl 3):3–11.
- Patil S, Bergula A, Chen PC, Colwell CW Jr, D'Lima DD. Polyethylene wear and acetabular component orientation. *J Bone Joint Surg Am*. 2003;85(Suppl 4):56–63.
- Resubal JR, Morgan DA. Computer-assisted vs conventional mechanical jig technique in hip resurfacing arthroplasty. *J Arthroplasty*. 2009;24:341–350.
- Romanowski JR, Swank ML. Imageless navigation in hip resurfacing: avoiding component malposition during the surgeon learning curve. *J Bone Joint Surg Am*. 2008;90(Suppl 3):65–70.
- Saxler G, Marx A, Vandevelde D, Langlotz U, Tannast M, Wiese M, Michaelis U, Kemper G, Grutzner PA, Steffen R, von Knoch M, Holland-Letz T, Bernsmann K. The accuracy of free-hand cup positioning—a CT based measurement of cup placement in 105 total hip arthroplasties. *Int Orthop*. 2004;28:198–201.
- Schnurr C, Michael JW, Eysel P, König DP. Imageless navigation of hip resurfacing arthroplasty increases the implant accuracy. *Int Orthop*. 2009;33:365–372.
- Seyler TM, Lai LP, Sprinkle DI, Ward WG, Jinnah RH. Does computer-assisted surgery improve accuracy and decrease the learning curve in hip resurfacing? A radiographic analysis. *J Bone Joint Surg Am*. 2008;90(Suppl 3):71–80.
- Steffen RT, Pandit HP, Palan J, Beard DJ, Gundle R, McLardy-Smith P, Murray DW, Gill HS. The five-year results of the Birmingham Hip Resurfacing arthroplasty: an independent series. *J Bone Joint Surg Br*. 2008;90:436–441.
- Wan Z, Malik A, Jaramaz B, Chao L, Dorr LD. Imaging and navigation measurement of acetabular component position in THA. *Clin Orthop Relat Res*. 2009;467:32–42.
- Williams D, Royle M, Norton M. Metal-on-metal hip resurfacing: the effect of cup position and component size on range of motion to impingement. *J Arthroplasty*. 2009;24:144–151.
- Williams S, Leslie I, Isaac G, Jin Z, Ingham E, Fisher J. Tribology and wear of metal-on-metal hip prostheses: influence of cup angle and head position. *J Bone Joint Surg Am*. 2008;90(Suppl 3):111–117.
- Wines AP, McNicol D. Computed tomography measurement of the accuracy of component version in total hip arthroplasty. *J Arthroplasty*. 2006;21:696–701.
- Witzleb WC, Hanisch U, Ziegler J, Guenther KP. In vivo wear rate of the Birmingham Hip Resurfacing arthroplasty: a review of 10 retrieved components. *J Arthroplasty*. 2009;24:951–956.
- Ybinger T, Kumpan W, Hoffart HE, Muschalik B, Bullmann W, Zweymüller K. Accuracy of navigation-assisted acetabular component positioning studied by computed tomography measurements: methods and results. *J Arthroplasty*. 2007;22:812–817.