



Early Cup Shifts: A Previously Unrecognized Phenomenon in Hip Arthroplasty

Dani Gaillard-Campbell MS* and Thomas P Gross

Midlands Orthopaedics and Neurosurgery, Blanding Street, Columbia, SC, USA

*Corresponding Author: Dani Gaillard-Campbell MS, Midlands Orthopaedics and Neurosurgery, Blanding Street, Columbia, SC, USA.

Received: November 20, 2019

Abstract

Background: Early postoperative acetabular component shifts are often missed due to inadequate x-rays. After initiating a policy at our practice to obtain standardized pelvic radiographs immediately after hip resurfacing surgery, we began noticing asymptomatic, spontaneous early cup shifts. With careful x-ray analysis, we discovered that the incidence of shift was 0.9% (12 of 1285 cases).

Methods: Our primary study purpose was to identify and evaluate risk factors for cup shift, with a secondary aim to determine if cup shifts affected clinical outcomes. We retrospectively collected radiographic data from our clinical database to determine cup shifts. We further analyzed follow-up data from this database to evaluate clinical outcomes.

Results: All cups became radiographically stable after the initial shift. Approximately 90% of these cases had excellent clinical outcomes, while 2 cases (9.5% of shifts) were revised: one early for extreme malposition, and the other late for impingement pain. In 95% of shifted cases, the acetabular component moved into a more horizontal position. Mean absolute value of shift was 17° (range 10° - 36°). There were no cases of abnormal metal ion levels, even in the case that steepened and exceeded the RAIL guideline. When we compared cases before and after the new wedge-fit protocol, we noticed a drop in the incidence of cup shifts from 0.9% to 0.2% ($p = 0.004$).

Conclusions: Cup shifts often occur early and are asymptomatic, making them difficult to diagnose. With a series of early x-rays, we discovered rate of shift at our practice was 0.9%. With a new wedge-fit method of preparing acetabula, rate of early cup shift decreased significantly to 0.2%.

Keywords: Previously; Unrecognized; Arthroplasty

Abbreviations

Mom: Metal-On-Metal; HRA: Hip Resurfacing Arthroplasty; AWRF: Adverse Wear-Related Failure; RR: Recovery Room; NSIOR: Normalized-To-Standing Intraoperative Radiographs; AP: Anterior-Posterior; AIA: Acetabular Inclination Angle.

Introduction

Background

Metal-on-metal (MoM) hip resurfacing arthroplasty (HRA) has excellent outcomes, especially in the young and active [1-4]. Many studies have investigated various HRA failure modes and complications to improve implant design, perioperative techniques, and

resulting clinical outcomes [5-10]. Of the categories investigated, none have focused on acetabular cup shifts. Some surgeons have reported individual spontaneous cup shifts (i.e. cup shifts not secondary to other failures) [11-13] but provided no explanations or solutions.

The lack of previous published outcomes may, in large part, be due to the difficult nature of diagnosing cup shifts. Spontaneous cup shifts are often asymptomatic [14], occur early [4,13,15], and become stable after the initial shift [4,14]. Therefore, without normalized intraoperative x-rays and immediate postoperative mea-

surements, many cup shifts can be missed altogether. As part of our effort to understand and prevent adverse wear-related failure (AWRF) [16], we began taking non-rotated supine recovery room (RR) pelvis x-rays in 2008, immediate postoperative standing radiographs in 2010, and normalized-to-standing intraoperative radiographs (NSIOR) in 2011. We noticed our first two cup shifts in late 2008. We hypothesized that improved initial implant stability might reduce the incidence of this problem and therefore implemented a new acetabular bone preparation method in 2012 that we named the “wedge-fit” method. Because wedge fitted uncemented femoral total hip stems have such reliable fixation [17,18], we reasoned that creating a similar wedge fit on the acetabular side might be beneficial.

Herein, we investigate the risk factors for cup shifts and the outcomes of our cup shift protocol. We prospectively collected patient data and performed retrospective analyses to explore the incidence of cup shifts before and after a newly implemented wedge-fit technique, identify risk factors for cup shifts, and determine the effect on cup shifts on clinical outcomes.

Methods

Radiographic protocol

Beginning in 2008, we collected a standardized supine non-rotated anterior-posterior (AP) pelvis x-ray on every patient immediately after surgery. Beginning in 2010, after ambulation, we took a standing AP pelvis x-ray prior to discharge from the facility. Additionally, we began taking more precise NSIOR in 2011 to meet strict criteria for acetabular placement that we had developed to prevent AWRF [16]. This now allowed comparison of intraoperative radiographs with follow-up standing x-rays. The acetabular inclination angle (AIA) was measured on all intra- and postoperative pelvic x-rays by multiple trained staff. Intraoperative x-rays are measured by the single, primary surgeon and confirmed by a trained x-ray technician. Postoperative x-rays are measured by the surgeon or head nurse and confirmed by trained office staff. In summary, our current protocol comprises collecting an AP pelvis radiograph at each of the following time periods: Preoperatively supine and standing, operating room “standing” NSIOR, RR supine, before facility discharge standing, at 6 weeks and 1 year both supine and standing, and we request standing x-rays at 1 year, 2 years and every other year thereafter.

Data collection

Between April 2008 and June 2016, we found 2846 HRA cases in our database with adequate serial pelvic x-rays and minimum

2-year follow-up, providing ample time to determine if a cup shift had occurred. Clinical, radiographic, and metal ion data as well as failures were recorded in Ortho Vault (Midlands Orthopaedics and Neurosurgery PA, Columbia, SC, USA) prospectively. Specifically, we recorded AIA from all intraoperative and all postoperative pelvic x-rays in our database. We also compared the incidence of “focal femoral narrowing” between shifted and non-shifted components. The sign for focal femoral narrowing has been described previously by Amstutz [19,20]. It is suspected to result when the femoral neck makes repetitive contact with the acetabular component edge in abduction, extension and external rotation of the hip. Thus, femoral narrowing likely indicates posterior-superior neck impingement on the cup edge.

Beginning in October 2010, we began recording when an acetabular component was repositioned intraoperatively. We requested routine whole blood cobalt and chromium levels at 2 years follow-up. If the laboratory reported plasma or serum metal ion levels, we converted them to whole blood levels by the Smolders’ method [21]. We categorized each metal ion level results as either normal, optimal, acceptable, and problematic and potentially toxic. The rationale for these categories has been described previously [22].

Implants

All cases were performed using the same hemispherical Biomet Magnum™ cobalt chrome acetabular component with titanium alloy plasma spray coating. The implant thickness is 6 mm at the apex and 3 mm at the rim. Four pairs of small fins provide additional rotational control.

Identifying shifts

Intraoperative x-rays are measured by the single, primary surgeon and confirmed by a trained x-ray technician. AIA is measured by running a horizontal control line along the bottom of the ischium and another measurement line running through the bottom lips of the acetabular cup (Figure 1). Postoperative x-rays are measured by the surgeon or head nurse and confirmed by trained office staff. We define cup shift by change in AIA on equivalent x-rays by more than 10 degrees (Table 1). Anything less is often a result of the implant seating in or small measurement variabilities. When a potential shift was identified, the surgeon measured x-rays again and directly compared side-to-side equivalent pelvic x-rays (supine vs. supine and standing vs. standing). We do not compare supine with standing x-rays; we believe that comparison of equivalent x-rays (supine with supine, standing with standing) provides a justifiable

assessment of cup shift, which can occur in the sagittal or frontal/coronal plane. If, after measurements by the two trained staff with a confirmation evaluation from the surgeon, the cup shows a difference in over 10 degrees, it is categorized as a cup shift.

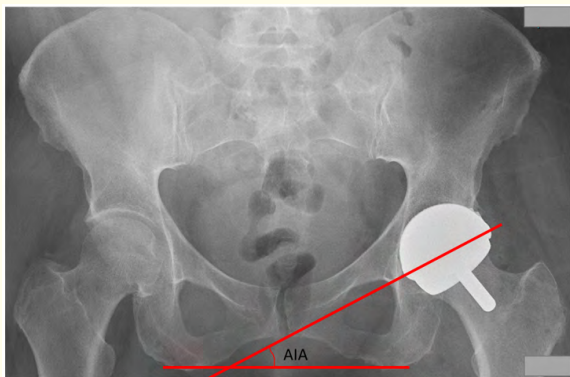


Figure 1: Presents the method of obtaining the acetabular inclination angle by running a horizontal line along the bottom of the ischium and another line running through the bottom lips of the acetabular cup.

Cup Shifts (n=21)	
Outcome	
#, % Revised	2 (9.5%)
#, % Stable after shift	19 (90.5%)
Time to Shift (#, %)	
Immediate Standing	9 (42.9%)
Before 6 weeks	9 (42.9%)
Unknown	3 (14.3%)
Type of Shift (#, %)	
Flattened	20 (95.2%)
Steepened	1 (4.8%)

Table 1: Characterization of Cup shifts.

Surgical method

In 2012, we introduced the new “wedge-fit” acetabular preparation technique that we hoped would improve initial implant stability (decrease cup shifts). Until November 2011, all acetabulae were under reamed by 1-mm less than the outer diameter of the component. Afterwards, reaming was adjusted for bone density. All patients had a preoperative DEXA scan performed. Only soft

bone (T-score<-1.0) was now under reamed 1-mm; this is achieved with a final reamer sized 1-mm less than the outer diameter of the implanted cup. In “good bone” or “hard bone” (T-score≥-1.0), the acetabulum was reamed line-to-line with the outer diameter of the cup. Finally, we added an “apex relief” in all cases starting in June 2012; a “wedge-fit” was created by removing 2-mm of apex bone with a small, clean reamer (5-mm smaller than the final reamer) just prior to component implantation (Figure 2). We placed a metal trial component that was approximately line-to-line with the final component into the reamed socket to judge the reaming depth; this assisted in correct positioning of the component with respect to inclination, anteversion, and cup overhang. The hypothesis for this “wedge-fit” reaming method was that softer bone requires more press fit; also, it is best to avoid bottoming out the component so it will not “toggle” on the apex. Instead, it should wedge more tightly into the periphery with loading during gait. The entirety of the “wedge-fit” acetabular preparation protocol was in place by June 2012.

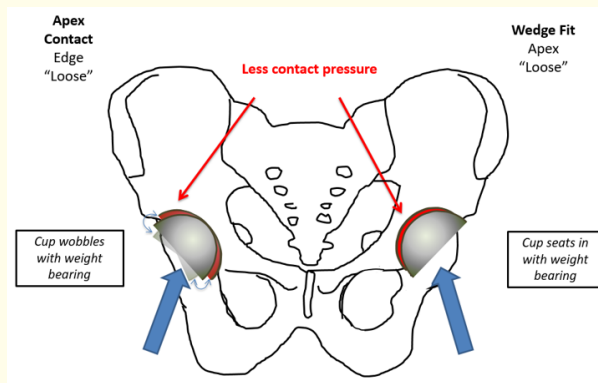


Figure 2: Illustrates acetabular cup placement and fixation with and without the wedge-fit reaming technique.

Study groups

We defined Group A as cases with no shift and Group B as cases with identified shift. Demographics are listed in table 2. To assess differences in clinical outcomes between patients with and without cup shift, we compared functional scores (Table 3). Further, we identified 10 patients with bilateral HRA in which only one side shifted and compared clinical outcomes we between their shifted and non-shifted hips. We present blood ion data for these cases in table 4.

Variable	Group A (No Shift)	Group B (Cup Shift)	P-value
Date Range	4/2008-6/2016		--
# of Cases	2825	21	--
<i>Demographics</i>			
# Female	745 (26.4%)	7 (33.3%)	0.4715
Age (Years)	53.6 ± 8.3	53.6 ± 9.8	1.000
BMI	27.7 ± 4.7	27.9 ± 5.7	0.8462
T-Score	0.0 ± 1.2	-0.3 ± 1.1	0.2536
# Osteoarthritis	2222 (78.6%)	16 (76.2%)	0.7872

Table 2: Demographics (No Shift vs Cup Shift).

Variable	No Shift (N=2825)	Cup Shifted (N=21)	P-value
<i>Postoperative</i>			
HHS Score	98.3 ± 5.8	98.5 ± 2.4	0.8746
HHS Pain Score	42.9 ± 4.0	42.8 ± 1.9	0.9089
UCLA Score	7.5 ± 2.0	7.0 ± 2.4	0.2546
VAS ² Pain: Regular	0.2 ± 0.8	0.2 ± 0.6	1.000
VAS Pain: Worse	1.3 ± 2.1	1.9 ± 3.0	0.1939
Groin Pain (# cases, %)	109 (7.1%)	1 (7.7%)	0.8572
Normal Metal Ions (# cases, %)	1307/1330 (98.3%)	16/16 (100%)	0.5961

Table 3: Clinical Outcomes (No Shift vs Cup Shift).

Variables	No shift			Shifted			P-values between Group I and Group II	
	Unilateral (N=1565)	Bilateral (N=1260)	P-value	Unilateral (N=11)	Bilateral (N=10)	P-value	Unilateral	Bilateral
#, % Patients Tested	1330/2825 (47.1%)		--	16/21 (76.2%)		--	0.0063*	
Mean Co	1.1 ± 1.2	1.7 ± 2.0	<0.0001*	1.1 ± 0.5	1.1 ± 0.5	1.000	1.000	0.5492
Mean Cr	0.8 ± 0.9	1.3 ± 1.5	<0.0001*	1.0 ± 0.6	0.7 ± 0.3	0.3605	0.4433	0.4245
Normal (#,%)	641 (80.6%)	313 (58.5%)	<0.0001*	9 (75%)	3 (75%)	1.000	0.6241	0.5029
Optimal (#, %)	776 (97.6%)	522 (97.6%)	0.9601	12 (100%)	4 (100%)	1.000	0.5892	0.7490
Acceptable (#,%)	17 (2.1%)	8 (1.5%)	0.3953	0 (0.0%)	0 (0.0%)	1.000	0.6101	0.8026
Problematic (#, %)	2 (0.3%)	4 (0.7%)	0.1868	0 (0.0%)	0 (0.0%)	1.000	0.8650	0.8650
Toxic (#, %)	0 (0.0%)	0 (0.0%)	0.2225	0 (0.0%)	0 (0.0%)	1.000	1.000	1.000

Table 4: Blood Metal Ion Data.

Statistical analyses

We performed a multivariate analysis to determine what factors might affect the incidence of cup shifts (Table 5). ANCOVA was performed using XLSTAT (Addinsoft, New York, NY). In all other

comparisons, a Students' t-test was used to compare averages, and a two-population Z-test was used to compare ratios. All statistical analyses were carried out at a 95% confidence interval.

Source	Value	Standard error	t	Pr > t	Lower bound (95%)	Upper bound (95%)
Intraoperative AIA	0.001	0.000	1.040	0.298	0.000	0.001
T-score	-0.001	0.002	-0.450	0.653	-0.004	0.003
Implant Size	-0.001	0.001	-1.362	0.173	-0.003	0.000
Age	0.000	0.000	-0.156	0.876	-0.001	0.000
BMI	0.000	0.000	0.696	0.486	-0.001	0.001
Diagnosis	0.005	0.005	0.919	0.358	-0.005	0.014
Wedge-fit	0.011	0.005	1.972	0.049*	0.000	0.021
Cup Repositioned	-0.004	0.006	-0.578	0.563	-0.016	0.009
Sex	0.004	0.006	0.580	0.562	-0.009	0.016

Table 5: Linear Regression Multivariate Analysis/ANCOVA.

Ethics approval

This retrospective analysis is exempt from IRB review based on 45 CFR 46, "Collection or Study of Existing Data", considering the HIPPA Privacy Rule (45 CFR 160 and 164a); this has been confirmed by the IRB at Providence Hospital in Columbia, SC.

Results

These data show that about half of the shifts (42.9%) occurred the first time the patient walked, while the same amount (42.9%) occurred by the initial 6-week follow-up x-ray (Table 1). These cups did not appear to result in failure of bone ingrowth (defined as acetabular loosening before 3 years), as we originally feared. All components stabilized by 6 weeks from the initial shift. Most cups (95%) shifted to a relatively more horizontal position and stayed under the RAIL. Mean absolute value of shift was 17° with a range of 10° to 36°.

There were no differences in demographics between cases with and without shifts (Table 2). Rate of repositioning intraoperatively was no different between cases with and without shifts. While the number of "small" implants (< 48 mm bearing) was similar, the mean component size for shifted cups was significantly smaller (48.1 ± 3.7 mm for shifted cups vs 49.8 ± 3.5 mm for no shift, $p = 0.03$). Rate of apex relief was significantly higher among non-shifted cases (51.4% vs 28.6%, $p = 0.04$).

Excluding the two failures, there was no difference in clinical score between shifted and non-shifted cups. Of the patients with shifted components, ten received bilateral HRA. We compared pain scores and range-of-motion between both sides for each individual patient; for equal postoperative intervals, pain scores were the equal between hips for the same patient. Function scores varied by an average of two between bilateral hips (range 0 - 14), and range-of-motion varied by an average of three degrees between bilateral hips (range 0-20°).

When comparing 2-year blood ion levels between cases with and without cup shift (Table 4), we found an analysis of outliers more telling than comparing mean levels. In the cup shift group, 16 of 21 patients (76%) complied with ion testing requests; all 16 cases had either "normal" or "optimal" ion levels. Among non-shifted cases with metal ion results (47.1%), 97% of metal ion results fell into these categories. In this group, 2.5% had "acceptable" levels,

and another 0.5% had "problematic" ion levels. Mean metal ion levels were largely similar between both groups: whole blood cobalt and chromium levels in unilateral patients were 1.2 µg/L and 0.9 µg/L, respectively. All cases of AWRF were revised and are listed as separate failures (4 non-shifted cases; 0 shifted cases); their ion levels are not included in Table 4. AWRF is predicted by metal ions greater than 20 µg/L and confirmed during revision surgery with the presence of metallic fluid collection.

There were 38 failures (1.0%) that required revision surgery among cases without cup shift. There were 2 implant failures (10%) in cases with cup shifts. One cup shift case was revised early for extreme cup shift (36° to 0°) with excessive anteversion. A second case of cup shift was revised at 4 years due to hip impingement. At their 2-year follow-up, the patient had an activity score of 9 out of 10, HHS of 96, and optimal ion levels. At 4 years, he presented with impingement symptoms. A cup revision back to the original implanted position was recommended, but the patient elected to have a revision to a total hip replacement elsewhere with unknown outcome. Overall rate of failure was statistically different between shifted and non-shifted cases ($p = 0.002$); however, this rate was no longer significantly different when excluding the elected revision ($p = 0.18$).

The one unrevised case that shifted into a steeper position outside of the RAIL did not develop AWRF. This case had a 46-mm bearing size, with a RAIL limit of 40°. The cup shifted from 36° to 49°. The cup became stable after the shift and thus did not require revision. The patient had optimal ion levels at 4 years postoperative and HHS of 100 at their latest follow-up (8 years postoperative). Overall, shifted cups had a significantly lower AIA than non-shifted cups ($p < 0.0001$).

The multivariate analysis (Table 5) exposed just one variable that influences rate of cup shift. The wedge-fit preparation significantly reduced cup shifts ($p = 0.049$). This compares with the Z-test comparing rate of apex relief between shifted and non-shifted cases, which showed that apex relief was significantly lower among cup shifts ($p = 0.04$). The ANCOVA suggests that none of the following variables had a significant influence on cup shift: age, sex, T-score, intraoperative AIA, diagnosis, implant size, BMI or intraoperative component repositioning.

Discussion

Previously, we failed to notice acetabular component shifts until we began regularly collecting non-rotated standardized AP pelvis x-rays in the RR. To better understand these often-asymptomatic acetabular shifts, we performed a retrospective analysis of a single-surgeon MoM HRA cohort without and with cup shifts. The ANCOVA outcomes showed the wedge-fit technique significantly reduced risk of cup shifts. This compared with our Z-test results, showing that rate of apex relief is significantly lower among cup shifts. Furthermore, clinical outcomes were not significantly different for cases with or without cup shift.

It is difficult to predict which hip implants are likely to shift, and without regular radiographs, it is also challenging to recognize change in acetabular position. Demographics were similar between shifted and non-shifted cases, suggesting that no age, gender, diagnosis, or weight group is more at risk for change in acetabular position. Patients with cup shifts were no more likely than other patients to experience pain ($p = 0.50$). Average clinical scores were similar between cases with and without cup shift. When comparing individual bilateral HRA patients with one shifted cup and the other with no change in position, the pain and range-of-motion of both hips were similar.

Steep cups are known to correlate with higher levels of metal ions in the blood [24-26]. Therefore, one might think shifted cups should cause concern over metal wear. However, we have found that most cups shift into a more horizontal position (95%) and are stable for at least 2-years thereafter, indicating that they became bone ingrown. The metal ion data for our cohort showed that cobalt and chromium levels were similar between patients with shifted and non-shifted cups. There were no high-level outliers among the shifted cups. All shifted cases presented optimal ion levels.

There are several limitations to this study. First, we did not begin taking immediate standing postoperative x-rays until 2007 or NSIOR until 2011. The x-ray protocol was gradually improved and was not fully in place until 2011. However, the AP supine RR radiographs and follow-up supine x-rays were in place from the onset of the study. Therefore, it is unlikely that we missed any extreme cup shifts. Next, until the NSIOR and early standing postop x-rays were in place, we were not able to determine precise timing of the

initial shift. Consequently, we list 3 shifted cases as unknown time of shift. However, all other shifts occurred before 6 weeks and then stabilized. A third limitation is that we only studied shifts over 10° . It is possible there were other shifts of less magnitude. We chose 10° because we were confident that we could identify this degree of shift within the variability of our x-ray technique. Because we found that the studied shifts did not usually cause problems, lesser degrees of early shift are unlikely to either.

A component shift in the first 6 weeks would normally raise concern of failure of ingrowth. However, we found that this phenomenon more likely represents the bedding in of an acetabular component which then becomes stable. Therefore, unless the new cup position is extreme, we advise waiting. Few shifts require revision, in our experience (9.5%). To better detect these shifts, we recommend collecting multiple pelvic x-rays with neutral rotation at several time intervals. These should be stored in a digital file to facilitate comparison.

Conclusions

In summary, asymptomatic early cup shifts are a previously unrecognized problem that we only discovered after instituting a rigorous x-ray protocol in 2007. In all studied cases, the component stabilized, which no subsequent shifting. In most cases, the acetabular component shifts to a more horizontal position and therefore does not adversely affect wear. In most shifts, clinical outcome is excellent with no effect on range-of-motion. We found that shifts occurred in 0.9% of cases with 1-mm under-reaming; shifts were significantly reduced to 0.2% with a wedge-fit preparation technique. Our ANCOVA analysis also suggests the wedge-fit method decreases risk of shift. Other demographic factors do not seem to indicate an at-risk group. Repositioning acetabular components to optimize cup position does not increase rate of shift; we suggest intraoperative repositioning when required to meet the RAIL criteria and avoid edge loading. Our final recommendation to minimize shift is to use a wedge-fit preparation technique with intraoperative cup repositioning to meet RAIL guidelines; additionally, multiple x-rays should be taken to properly diagnose acetabular shifts.

Declarations

Ethics approval and consent

We present a retrospective analysis of prospectively collected data, with patient information withheld. This type of study is exempt from IRB review based on 45 CFR 46, "Collection or Study

of Existing Data”, considering the HIPPA Privacy Rule (45 CFR 160 and 164a).

Availability of data

Raw data is available upon request. Please contact Dani Gaillard-Campbell at dani.gaillard@midorthoneuro.com.

Competing Interests

We report no conflicts of interest.

Funding

This study was funded internally in full by the primary surgeon and Midlands Orthopaedics and Neurosurgery. The research department staff is paid for by Midlands Orthopaedics and Neurosurgery surgeons.

Authors' contributions

All authors contributed to this work. The senior author (TPG) was responsible for study design, initial draft, and proofreading. The corresponding author (DGC) was responsible for data collection and analysis, initial draft, and proofreading.

Acknowledgements

We have no acknowledgements to declare.

Bibliography

1. Le Duff MJ and Amstutz HC. “The Relationship of Sporting Activity and Implant Survivorship After Hip Resurfacing”. *Journal of Bone and Joint Surgery* 94 (2012): 911.
2. Fisher NE and Killampalli VV. “Sporting and physical activity following hip resurfacing”. *International Orthopaedics* 35 (2011): 977-980.
3. Amstutz HC., et al. “Resurfacing THA for patients younger than 50 year: results of 2- to 9-year followup”. *Clinical Orthopaedics and Related Research* 460 (2007): 159-164.
4. Gaillard MD and Gross TP. “Metal-on-metal hip resurfacing in patients younger than 50 years: A retrospective analysis”. *Journal of Orthopaedic Surgery and Research* 12.1 (2017): 1-12.
5. Kim PR., et al. “Causes of early failure in a multicenter clinical trial of hip resurfacing”. *The Journal of Arthroplasty* (2008).
6. Morlock MM., et al. “Modes of implant failure after hip resurfacing: morphological and wear analysis of 267 retrieval specimens”. *Journal of Bone and Joint Surgery* 90.3 (2008): 89-95.
7. Langton DJ., et al. “Early failure of metal-on-metal bearings in hip resurfacing and large-diameter total hip replacement A Consequence of Excess Wear”. *Journal of Bone and Joint Surgery* 92 (2010): 38-46.
8. Gross TP and Liu F. “Risk factor analysis for early femoral failure in metal-on-metal hip resurfacing arthroplasty: the effect of bone density and body mass index”. *Journal of Orthopaedic Surgery and Research* (2012): 7.
9. Yue EJ., et al. “Hip Resurfacing Arthroplasty Risk Factors for Failure Over 25 Years”. *Clinical Orthopaedics and Related Research* 467 (2009): 992-999.
10. Morlock MM., et al. “Date unknown Biomechanical, morphological, and histological analysis of early failures in hip resurfacing arthroplasty”. (2006).
11. Mont MA., et al. Resurfacing is Comparable to Total Hip Arthroplasty at Short-term Follow up (2008).
12. Lewinnek GE., et al. “Dislocations after total hip-replacement arthroplasties”. *Journal of Bone and Joint Surgery* 60.2 (1978): 217-220.
13. Mont MA., et al. “Resurfacing is comparable to total hip arthroplasty at short-term followup”. *Clinical Orthopaedics and Related Research* 467.1 (2009): 66-71.
14. Blaha JD. Well-Fixed Acetabular Component Retention or Replacement the Whys and the Wherefores.
15. McGrath MS., et al. “Total hip resurfacing in patients who are sixty years of age or older”. *The Journal of Bone and Joint Surgery American* 90.3 (2008): 27-31.
16. Liu F and Gross TP. “A safe zone for acetabular component position in metal-on-metal hip resurfacing arthroplasty: winner of the 2012 HAP Paul award”. *The Journal of Arthroplasty* 28.7 (2013): 1224-1230.
17. Bottner F., et al. “Implant migration after early weightbearing in cementless hip replacement”. *Clinical Orthopaedics and Related Research* 436 (2005): 132-137.
18. Aldinger PR., et al. “Uncemented grit-blasted straight tapered titanium stems in patients younger than fifty-five years of age. Fifteen to twenty-year results [Internet]”. *The Journal of Bone and Joint Surgery American* 91.6 1432-1439.

19. Beaulé PE., *et al.* "Risk Factors Affecting Outcome of Metal - on - Metal Surface Arthroplasty of the". *Hip* 418 (2004): 87-93.
20. Takamura KM., *et al.* "Incidence and Significance of Femoral Neck Narrowing in the First 500 Conserve® Plus Series of Hip Resurfacing Cases: A Clinical and Histologic Study". *Orthopedic Clinics of North America* 42.2 (2011): 181-193.
21. Smolders JMH., *et al.* "Metal ion interpretation in resurfacing versus conventional hip arthroplasty and in whole blood versus serum. How should we interpret metal ion data?" *HIP International* 21.5 (2011): 587-595.
22. Liu F and Gross TP. "A safe zone for acetabular component position in metal-on-metal hip resurfacing arthroplasty: Winner of the 2012 HAP Paul award". *The Journal of Arthroplasty* 28.7 (2013): 1224-1230.
23. Pramanik S., *et al.* "Chronology of total hip replacement and materials development". *Trends in Biomaterials and Artificial Organs* 19 (2005):15-26.
24. Beaulé PE., *et al.* "Risk factors affecting outcome of metal-on-metal surface arthroplasty of the hip". *Clinical Orthopaedics and Related Research* 418 (2004): 87-93.
25. Langton DJ., *et al.* "Reducing Metal Ion Release Following Hip Resurfacing Arthroplasty". *Orthopedic Clinics of North America* 42.2 (2011):169-180.
26. Malviya A and Holland JP. "Pseudotumours associated with metal-on-metal hip resurfacings". *Acta Orthopaedica Belgica* 75.4 (2009):477-483.

Volume 3 Issue 1 January 2020

**© All rights are reserved by Dani Gaillard-Campbell
MS and Thomas P Gross.**